

*Tikrit University*

*College of Nursing*

*Basic Nursing Sciences*



**Second Year - 2023-2024**

**Microbiology**

*Ascaris lumbricoides*

**by: assistant lecturer**

**Abdullah Musaa Kadhim**

## **Ascaris lumbricoides**

**It is cosmopolitan ,having a world –wide distribution,being specially prevalent in the tropics,such as Iraq ,China,India and South-East Asia.It is occurs in the persons with unhygienic habits.**

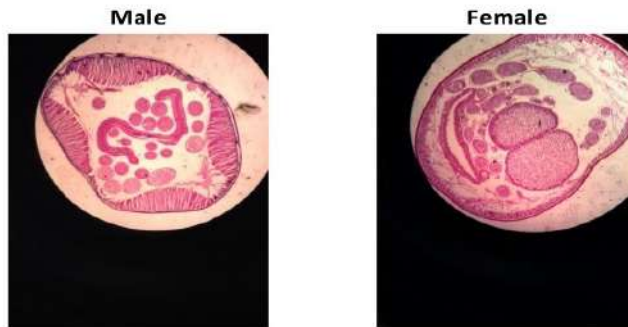
### **Habitat:**

**The adult worm lives in the luman of the small intestine(dudenoum-jejunum) .**

**Morphology: Adult worm resembles an ordinary earthworm and is the largest intestinal nematode parasitizing man.When fresh from the intestine,it is light brown or pink in colour, but it gradually changes to white.In shape it is rounded and tapers at both ends,the anterior end being thinner than the posterior .The mouth opens at the anterior end and possesses three finely toothed lips, one dorsal and two ventral.The digestive and reproductive organs float inside the body cavity containing an irritating fluid.**

	<b>Male</b>	<b>Famle</b>
<b>Size</b>	<b>15-25 cm in length 3-4 mm diameter</b>	<b>25-40 cm in length 5-8 mm diameter</b>
<b>Posterior part</b>	<b>The end is curved ventrally, and form copulatory bursa with two spicules.</b>	<b>The posterior is conical and straight Without spicules</b>
	<b>The cloaca is present</b>	<b>Lack cloaca</b>
<b>Anterior part</b>	<b>Provided with 3 lips</b>	<b>Provided with 3 lips</b>
<b>Vulvar waist</b>	<b>absent</b>	<b>present</b>

Ascaris lumbricoides (cross-section)

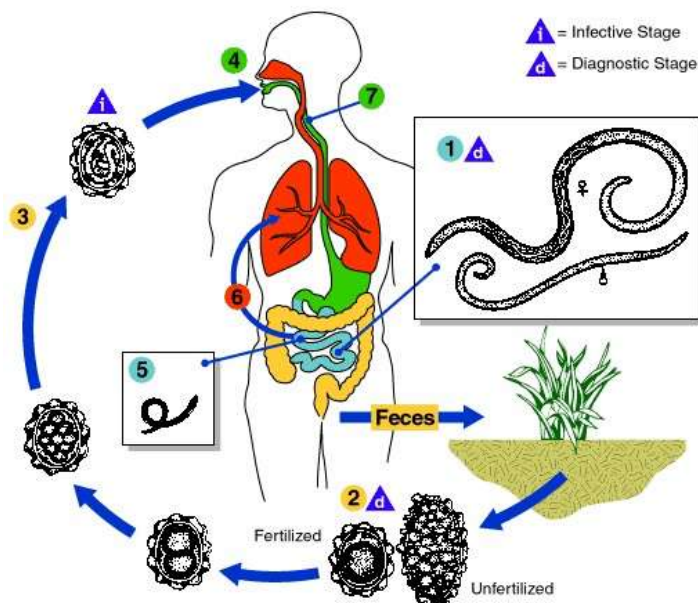
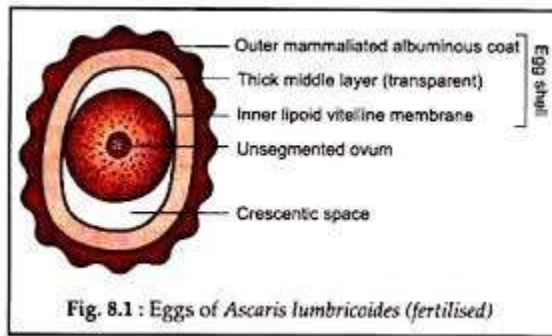


LIRALAIN MANALO - 3EMT

**Egg**:-The egg –laying capacity of mature female *A.lumbricoides* has been found to be enormous about 200,000 egg daily. Both fertilized and unfertilized eggs may be found in a sample of stool but if a specimen shows only the unfertilized eggs, it signifies that the host is harbouring female *Ascaris* or mating between males and females has not occurred. The egg consists of the following observable structures:-

- 1-Unsegmented ovum with crescentic space in fertilized egg only.
- 2-Inner lipoid layer(this layer absent in unfertilized egg)
- 3-Thick middle layer (Chitinous layer)
- 4-Outer mammillated ,albuminous coat.(protein layer)

	Fertilized egg	Unfertilized egg
Shape	rounded	Elongated – narrower
Size	60-70 mm in length 40-50 mm in breadth	80 mm in length 55 mm in breadth
Embryo	Un developed unicellular embryo	Unembryonated ovum with a mass disorganised
Shell	thick	Thin
Other features	Usually corticated	May be corticated or decorticated



**Life cycle**:- The diagram above reflects the life cycle of *Ascaris lumbricoides*.

Adult worms ① live in the lumen of the small intestine. A female may produce approximately 200,000 eggs per day, which are passed with the feces ②. Unfertilized eggs may be ingested but are not infective. Fertile eggs embryonate and become infective after 18 days to several weeks ③, depending on the environmental conditions (optimum: moist, warm, shaded soil). After infective eggs are swallowed ④, the larvae hatch ⑤, invade the intestinal mucosa, and are carried via the portal, then systemic circulation to the lungs ⑥. The larvae mature further in the lungs (10 to 14 days), penetrate the alveolar walls, ascend the bronchial tree to the throat, and are swallowed ⑦. Upon reaching the small intestine, they develop into adult worms ①. Between 2 and 3 months are required from ingestion of the infective eggs to oviposition by the adult female. Adult worms can live 1 to 2 years.

**Note: Four moltings of the larva occur-one outside while within the egg-shell ,two in the lungs and one in the intestine.**

**Diagnosis: This may be described under two heads:-**

**I-Direct evidences :**

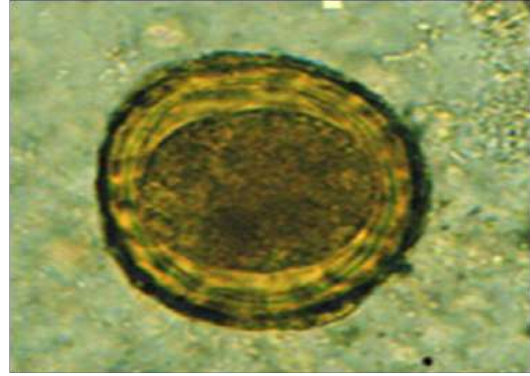
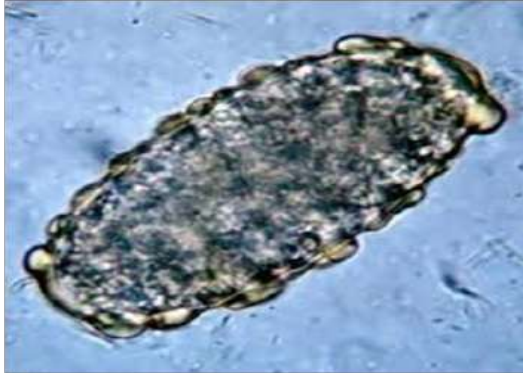**a-Finding adult worms in the stool or be vomited or scape through nares.**

**b-X-Ray c-Finding eggs in the stool by a direct microscopical examination ,and finding eggs in the bile by microscopical examination of the bile obtained by duodenal intubation may be reveal Ascaris eggs.**

**2- Indirect evidence**


**a-Blood examination to exam eosinophilia.**

**b-Serological tests are useful in diagnosis of extraintestinal ascariasis(Loeffler`s syndrome.)**

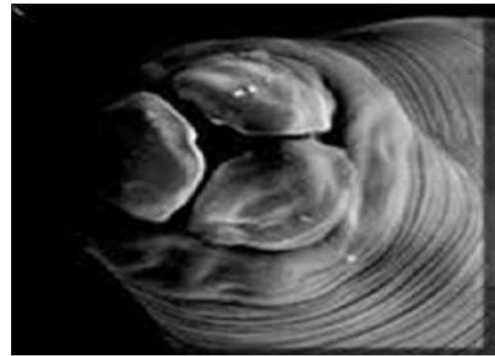


**unfertilised egg of**

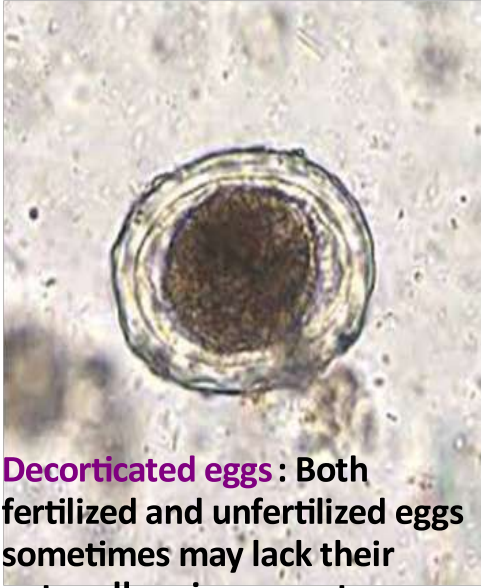***A.lumbricoidis* elongated fertilised egg, of and narrower than  
*A.lumbricoidis* unicellular fertilised egg stage as pass in the stool**



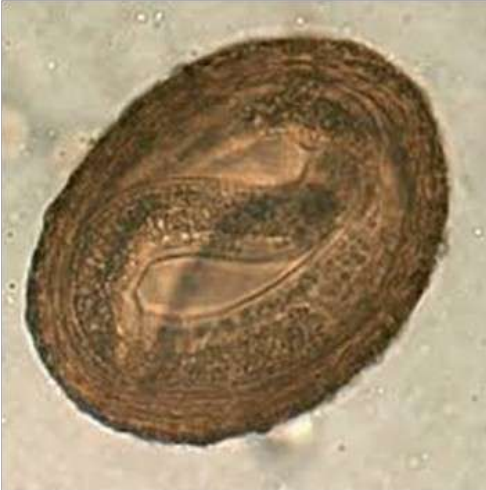**Anterior part of  
Adult male & female of  
*A.lumbericodis***



***A.lumbricoidis* provide  
with 3 lips**



**Decorticated eggs** : Both fertilized and unfertilized eggs sometimes may lack their outer albuminous coats



**embryonated egg infective stage**