

*Tikrit University*

*College of Nursing*

*Basic Nursing Sciences*



**First Year - 2023-2024**

**Anatomy**

**first stage**

**(عنوان المحاضرة)**

***Skeletal system***

***by:***

***Asst. Lecturer:***

***Saif Mohammed Fanar***

## Human Skeleton :

The human skeleton contain about 206 bones, that serves five major functions :

1. The skeleton provides the framework which supports the body and maintains in shape.
2. The joints between bones allow movement.
3. The skeleton protects many soft organs such as : Skull protect the brain, eye and vertebrae protect the spinal cord.
4. Skeleton is the site of hematopoiesis, the development of blood cells, that takes place in the bone marrow.
5. Bone matrix can store calcium , and bone marrow store iron.

Human skeleton is made up of following parts :

### 1. Skull

- a. Bones of the cranium.
- b. Face.
- c. Lower jaw.

### 2. Bones of the trunk

- a. vertebral column or Spinal column.
- b. Ribs.
- c. Sternum.

### A: Vertebral column :

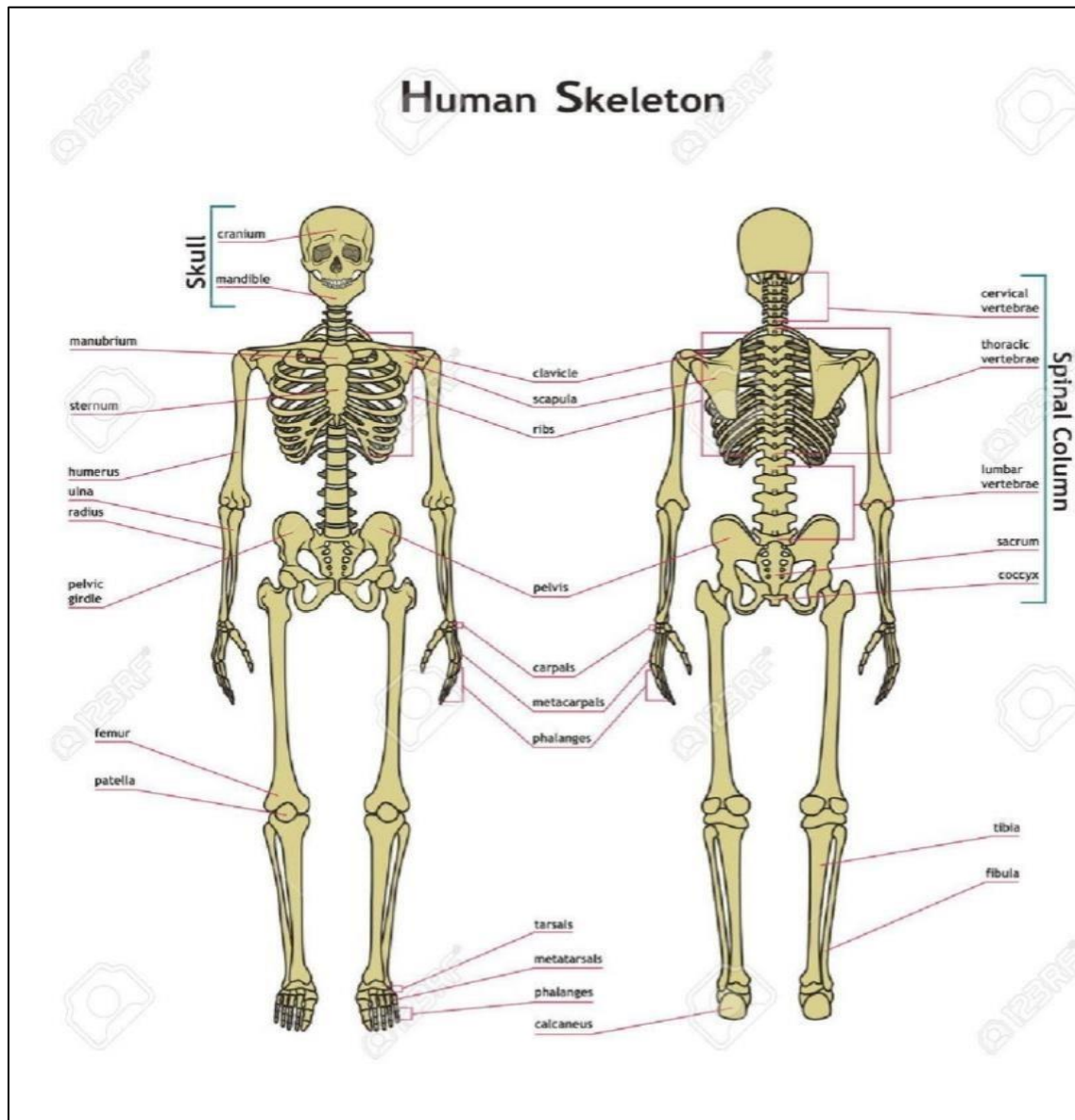
Consist of ( 33 ) vertebrae and divided into :

1. Cervical vertebra ( 7 ).
2. Thoracic or dorsal vertebra ( 12 ).
3. Lumbar vertebra ( 5 ).
4. Sacral vertebra ( 5 ).

5. Coccygeal vertebra ( 4 ).

### Types of bones :

1. Long bones :like ( femur , humerus , tibia , fibula , radius , ulna , etc. )
  2. Short bones : like ( clavicle , metacarpal, metatarsal, etc. )
  3. Flat bones : like ( skull bones , scapula , iliac , sternum )
- Irregular bones: like ( vertebrae, carpal, tarsal , sesamoid bone , etc. )



## B: Ribs

Are 12 pairs in number, articulate anteriorly with sternum and posteriorly with thoracic vertebra.

### Types of Ribs :

1. True ribs : 1-7 pairs ribs, connect to the sternum.
  2. False ribs : 8-10 pairs ribs, because they do not attach directly to the sternum.
- Floating ribs : 11,12 pairs ribs, because they have no connection with the sternum.

## C: Sternum

Is composed of three parts (bones), is a flat bone that forms in the anterior midline of the thoracic wall.

### 3. Bones of limbs together with shoulder and pelvic bones.

#### 1. Upper limbs

Bones of the shoulder girdle are :

a. Scapula

b. Clavicle

The bones of the upper limb which is attached to the shoulder girdle are these of :

#### 1. Arm

- humerus

#### 2. Forearm

- radius

- Ulna.

#### 3. Wrist joint - carpals (8).

#### 4. Metacarpals bones (5).

## 5. Phalanges (14).

Carpals bones are arranged in two rows of four bones each

Phalanges : there are three phalanges in each of the fifth-fingers and two phalanges only in the thumb.

## 2. Lower limbs

The bones of the lower limb which is attached to pelvic girdle are :

### 1. Thigh bone.

- femur

Is the longest, strongest bone in the body.

### 2. Patella.

### 3. Leg bones

a. Tibia

b. Fibula.

### 4. Ankle joint

- tarsals (7) .

The 2 tarsal bones is large and posterior and the 5 tarsal bones is small and anterior .

5. Metatarsals are five bones.

### 6. Toes.

- phalanges ( 14 ).

## JOINTS :-

Joints are the areas where 2 or more bones meet. Most joints are mobile, allowing the bones to move.

Joints consist of the following:

### 1- Cartilage:-

This is a type of tissue that covers the surface of a bone at a joint. Cartilage helps reduce the friction of movement within a joint.

## 2- Synovial membrane :-

A tissue called the synovial membrane lines the joint and seals it into a joint capsule. The synovial membrane secretes a clear, sticky fluid (synovial fluid) around the joint to lubricate it.

## 3- Ligaments :-

Strong ligaments (tough, elastic bands of connective tissue) surround the joint to give support and limit the joint's movement. Ligaments connect bones together.

## 4- Tendons :-

Tendons (another type of tough connective tissue) on each side of a joint attach to muscles that control movement of the joint. Tendons connect muscles to bones.

## 5- Bursas :-

Fluid-filled sacs, called bursas, between bones, ligaments, or other nearby structures. They help cushion the friction in a joint.

## 6- Synovial fluid :-

A clear, sticky fluid secreted by the synovial membrane.

## 7- Meniscus :-

This is a curved part of cartilage in the knees and other joints.

## The different types of joints :

There are many types of joints, including joints that don't move in adults, such as the suture joints in the skull. Joints that don't move are called fixed.

Other joints may move a little, such as the vertebrae.

Examples of mobile joints include the following :

- **Ball-and-socket joints :-**

Ball-and-socket joints, such as the shoulder and hip joints, allow backward, forward, sideways, and rotating movements.

- **Hinge joints :-**

Hinge joints, such as in the fingers, knees, elbows, and toes, allow only bending and straightening movements.

- **Pivot joints :-**

Pivot joints, such as the neck joints, allow limited rotating movements.

- **Ellipsoidal joints :-**

Ellipsoidal joints, such as the wrist joint, allow all types of movement except pivotal movements.

