

Tikrit University

College of Nursing

Basic Nursing Sciences



First Year - 2023-2024

English

(Title human skeleton)

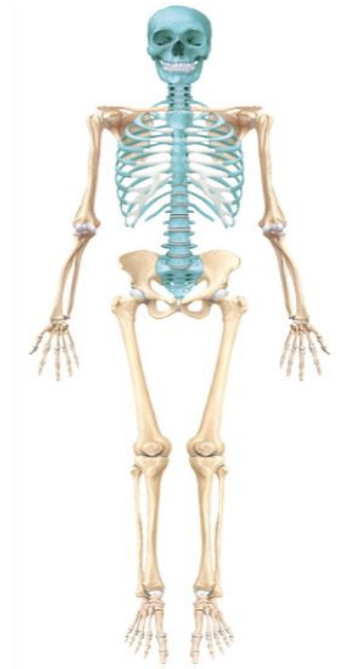by: by: Prof.Dr. Abdul-Jabbar Al-Samarrae

+ human skeleton

- around 206 bones in the adult
- The human skeleton is divided into two parts:

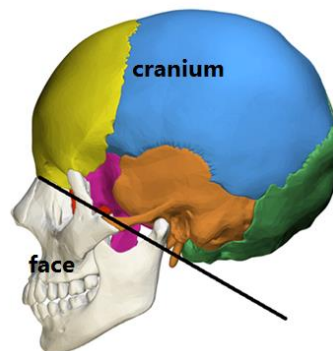
A. The axial skeleton.

- The axial skeleton forms the long axis of the body
- includes :
 1. the skull
 2. the vertebral column
 3. the Thoracic cage



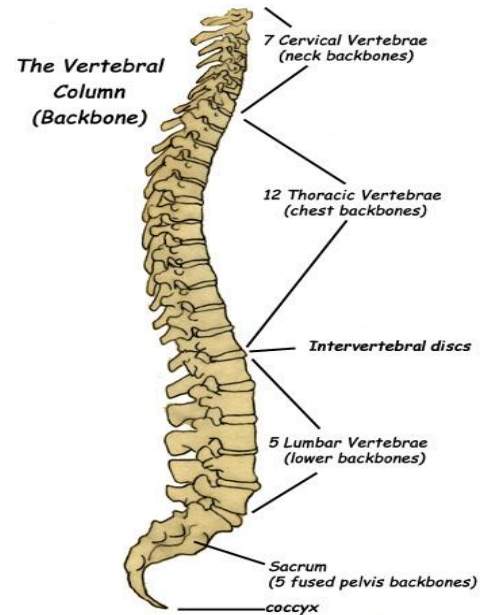
1. The skull:

- is the skeleton of head .it divides into:
- The bones of the Cranium
- The bones of the face



2. The vertebral column

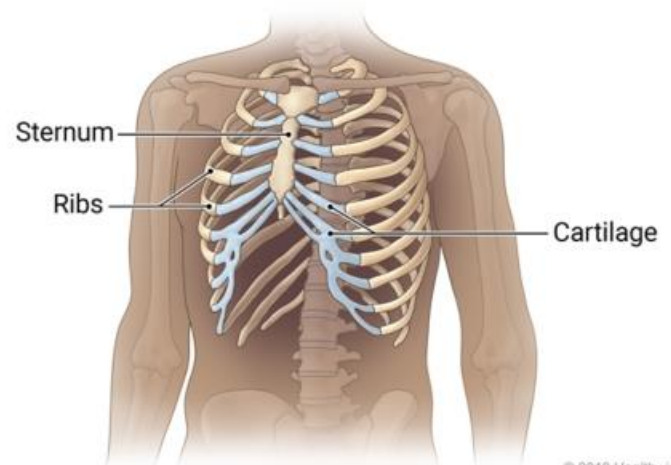
- The vertebral column extends from the skull to the pelvis
- It consists of
 - a. 7 Cervical vertebrae
 - b. 12 Thoracic vertebrae
 - c. 5 Lumbar vertebrae
 - d. Sacrum, (5 fused vertebrae)
 - e. Coccyx, (4 fused vertebrae).



3. The Thoracic cage: is formed by

(a)- Sternum

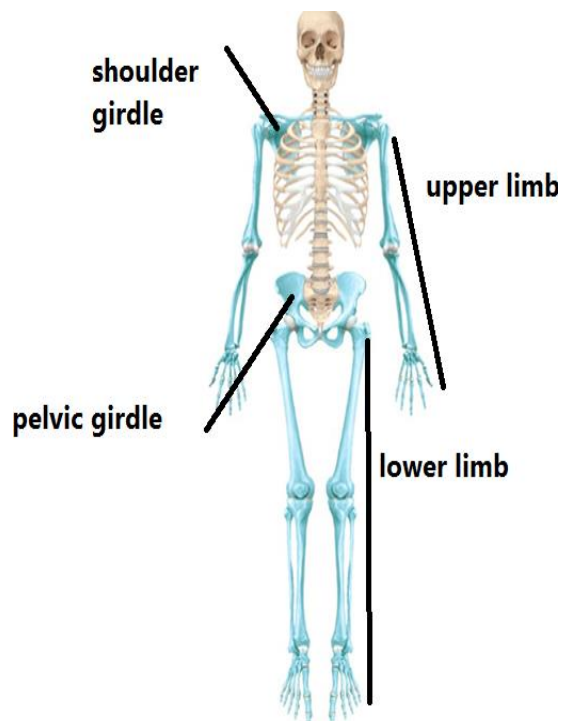
(b)- 12 pairs of ribs with their costal cartilage



© 2018 Healthwise

B-Appendicular skeleton: which includ .

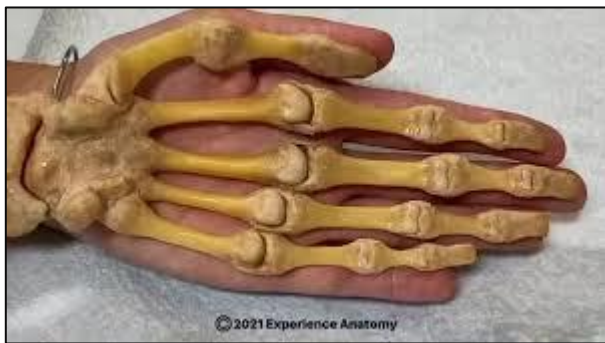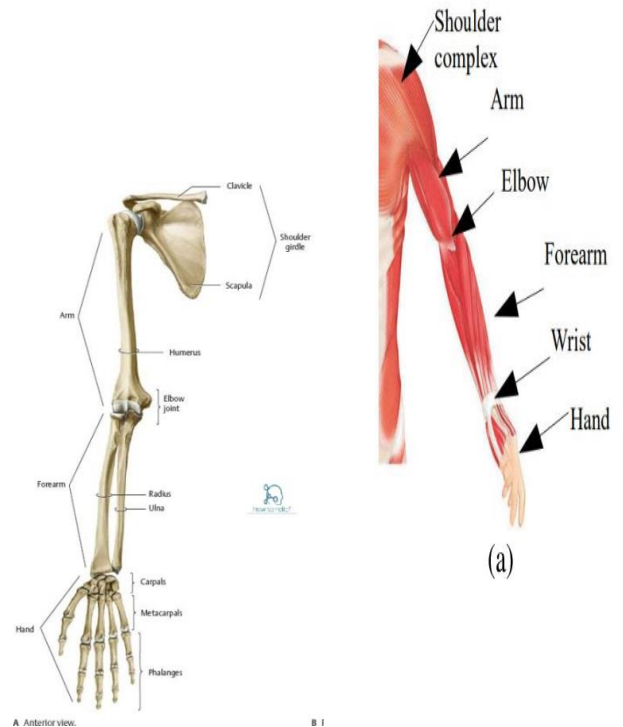
- 1) The **Upper limbs**
- 2) The **Lower limbs**
- 3) The **shoulder girdle**: provide connection point between the upper limb and axial skeleton
- 4) The **pelvis girdle**: provide connection points between the lower limb and axial skeleton



1. The Upper limbs

• bones of the upper limb ,it consists of the following:

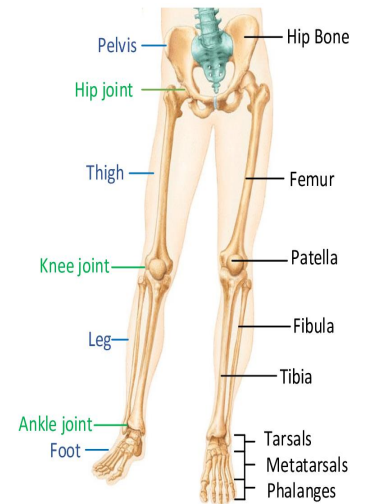
- a) Humerus : bone of the **arm**
- b) radius and ulna :bones of the **forearm**
 - the radius : lies on the lateral side of forearm
 - the ulna: lies on the medial side of forearm
- c) Carpal bones: bones of the **wrist**
- d) Metacarpals & Phalanges: Bones of the **hand**



2) The Lower limbs

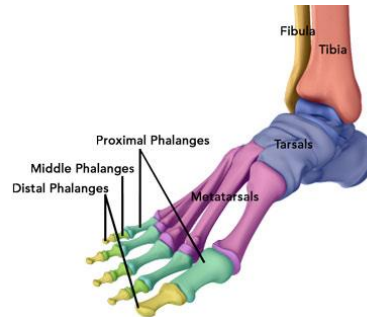
•bones of the lower limb, it consists of the following:

- a) Femur; bone of the **thigh**
- b) Tibia and fibula: bones of the **Leg**
 - the tibia : lies on the medial side of the leg
 - the fibula: lies on the lateral side of leg



C) Bones of the foot

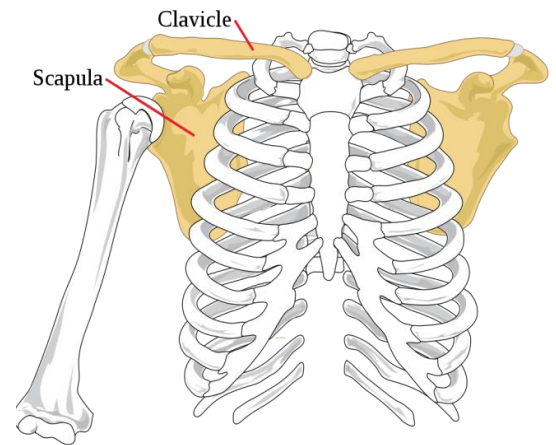
- Tarsal
- Metatarsal
- phalanges



3)The shoulder girdle

Bones of the shoulder girdle, it consists of the following

- clavicle**; is located on the upper front of the body
- scapula**; is located in the upper back of the body



4-Bones of the pelvic girdle.

- The pelvic girdle is formed by two hip bones
- Each hip bone consists of
 - Ilium
 - ischium
 - pubis

Hip Bones

